

South East London Area Prescribing Committee Clinical Guideline

Treatment of Wet Age-Related Macular Degeneration, Diabetic Macular Oedema, Central Retinal Vein Occlusion and Branch Retinal Vein Occlusion

Guideline Summary

This clinical guideline outlines the intravitreal treatment pathway for patients with neovascular age-related macular degeneration, diabetic macular oedema and macular oedema due to central or branch retinal vein occlusion.

Intravitreal Treatment Pathway

Document Detail	
Document Type	Clinical Guideline
Document name	Intravitreal Treatment Pathways for neovascular age-related macular degeneration, diabetic macular oedema, macular oedema due to central or branch retinal vein occlusion.
Document location	Individual Trusts
Version	Version 1.0
Effective from	01 April 2017
Review due date	01 April 2019
Owner	South East London Retina Steering Group
Author	<p>South East London Retina Steering Group</p> <p>Kings College Hospital NHS Foundation Trust Consultant Ophthalmologist Principal pharmacist clinical services, (Oct 2014- Aug 2017) Clinical Pharmacy Team Leader for Acute Surgery, Trauma, Planned surgery, Ophthalmology and Gastroenterology</p> <p>Guys and St Thomas' NHS Foundation Trust Consultant Ophthalmologist</p> <p>Clinical Commissioning Groups Joint Assistant Directors of Medicines Management NHS Greenwich CCG Chief Pharmacist NHS Southwark CCG Interface Pharmacist NHS Bromley CCG</p>
Approved by, date	South East London Area Prescribing Committee: April 2018
Superseded documents	0.0
Keywords	neovascular age-related macular degeneration (wAMD), diabetic macular oedema (DMO), central and branch retinal vein occlusion (CRVO, BRVO), ranibizumab, aflibercept, dexamethasone, intravitreal injection and laser

Change History		
Date	Change details, since approval	Approved by

Review History		
Date	Review details	Approved by

Date of approval: April 2018

Review date: April 2019

South East London Area Prescribing Committee. A partnership between NHS organisations in South East London: Bexley/ Bromley/ Greenwich/ Lambeth/ Lewisham
 Southwark Clinical Commissioning Groups (CCGs) & GSTFT/KCH/SLAM/Oxleas NHS Foundation Trusts & Lewisham & Greenwich NHS Trust

Not for commercial or marketing purposes. Strictly for use within the NHS

Contents

1. Scope of pathway	3
1.1 Dosing within the pathway	3
1.2 Known allergies	3
2. Wet Age-Related Macular Degeneration (Wet AMD)	4
2.1 Management of patients with vision remaining in only one eye	4
2.2 NICE criteria for starting treatment.....	4
2.3 Permanent Discontinuation of treatment	5
2.4 Temporary discontinuation of treatment	5
2.5 Switching treatments.....	5
2.6 In-tariff treatments.....	6
Photodynamic therapy (PDT)	6
Reference	6
Wet AMD clinic appointment schedule	7
Pathway for treatment of neovascular AMD with anti VEGF agents	8
3. Diabetic macular oedema (DMO)	9
3.1 NICE criteria	9
3.2 Choice of treatment agent.....	10
References	10
DMO clinic appointment schedule	12
Pathway for treatment of Diabetic Macular Oedema	13
.....	13
4. Central retinal vein occlusion	14
Ischaemic CRVO:	14
Non-ischaemic CRVO:	14
4.1 NICE guidance.....	14
4.2 Management of patients who do not respond to their first treatment	15
4.3 Use of bevacizumab	15
References	15
CRVO clinic appointment schedule	16
Central retinal vein occlusion (CRVO) treatment pathway	17
5. Branch retinal vein occlusion (BRVO)/ Hemi-vein occlusion (HVO).....	18
5.1 Switching treatments.....	18
5.2 Management of patients who do not respond after 3 injections	19
References	19
BRVO clinic appointment schedule; treatment with anti VEGF agent	20
BRVO clinic appointment schedule; treatment with dexamethasone	21
Pathway for treatment of Branch retinal vein occlusion (BRVO) with anti VEGF agents.....	22
Glossary.....	23

1. Scope of pathway

This pathway is intended to outline treatment for various conditions which all constitute macular pathology causing visual impairment. The pathway focuses on the use of intravitreal and laser treatment and incorporates recent NICE guidance in this clinical area.

1.1 Dosing within the pathway

Doses of the main treatments detailed within this pathway do not change in relation to patient factors. The doses are listed below.

Drug name	Dose	Presentation
Aflibercept	2mg	4mg/0.1ml Intravitreal injection
Ranibizumab	0.5mg	0.5mg in 0.05ml Intravitreal injection
Dexamethasone	700mcg	700mcg Intravitreal implant
Fluocinolone	190mcg	190mcg Intravitreal implant

1.2 Known allergies

A known allergy to any of the medications, or excipients within the formulation, will exclude a patient from treatment within that part of the pathway and an alternative sought where possible.

2. Wet Age-Related Macular Degeneration (Wet AMD)

Age-related macular degeneration (AMD) is a condition that leads to progressive loss of central vision. People who develop this condition will generally retain some peripheral vision but the ability to see well enough to recognise faces and drive safely may deteriorate rapidly.

Neovascular AMD (also known as wet AMD) is characterised by the development of immature blood vessels that grow from the choroid between the retinal epithelial cells and the photoreceptor cells in the centre of the retina. These new blood vessels can rupture and haemorrhage easily, causing the formation of lesions on the macular which then lead to visual impairment. Vascular endothelial growth factor (VEGF) is an endogenous protein which promotes the development of new blood vessels and increases vascular permeability and inflammation, all of which have been implicated in the development of AMD.

There are 26,000 cases of wet AMD a year and the condition is more common in women than men. The condition commonly affects people who are over 50 years old and the risk increases with age. The most common modifiable risk factor for the development of AMD is smoking tobacco. The risk of developing AMD is 3.6 times greater for current and former smokers compared to those who have never smoked before¹. The presence of drusen, yellow deposits within the eye, is the most accurate marker of AMD and the incidence of these deposits increases with age.

The National Institute for the Health and Care Excellence (NICE) recommends that the two agents aflibercept and ranibizumab are equally efficacious and there is little difference in cost (see costings appendix for drug cost of aflibercept 40mg/ml solution for intravitreal injection and ranibizumab 10mg/ml solution for intravitreal injection). The choice of treatment agent will be made by the clinician and the patient, taking patient-specific factors into account.

2.1 Management of patients with vision remaining in only one eye

Active management to avoid significant visual impairment is necessary for patients with vision remaining in only one eye that go on to develop AMD. These patients are carefully monitored and on some occasions it is appropriate to treat such a patient before they reach the NICE criteria for treatment.

This will normally represent a cost impact of one additional treatment with an anti VEGF agent. Treatment in this way is outside of NICE guidance.

The Consultant team estimate **50 patients** across South East London who fit the description above will be treated per annum.

2.2 NICE criteria for starting treatment

Treatment for AMD can only be started if all of the following criteria apply:

- Best possible visual acuity after correction with glasses or contact lenses is between 6/12 and 6/96
- There is no permanent damage to the fovea
- The area affected by AMD is no larger than twelve times the size of the area inside the eye where the optic nerve connects to the retina
- There are signs of active disease progression

Please note;

- Treatment should be stopped if the patient's vision deteriorates and there are changes inside the eye which demonstrate that the treatment is no longer working.

2.3 Permanent Discontinuation of treatment

Discontinuation of treatment should be considered in the following situations:

- A reduction, or no increase, in BCVA in the treated eye to less than 15 letters (absolute) on two consecutive visits in the eye, attributable to AMD in the absence of other pathology
- Reduction in the BCVA of 30 letters or more compared to either baseline and/or best recorded level since baseline as this may indicate either prior treatment effect or adverse effect or both
- There is evidence of deterioration of the lesion morphology
- Myocardial Infarction/Stroke – involve the patient in shared decision making at this stage. Most patients do not exit after consideration of the risks and benefits.
- A patient would exit the pathway after 12 months of monitoring without the need for drug treatment

2.4 Temporary discontinuation of treatment

This should be considered in patients who are stable and requires regular outpatient monitoring. Temporary discontinuation of treatment should be considered in the following circumstances:

- No persistent fluid in the absence of FFA leakage or no other evidence of disease activity in the form of increasing lesion size or no new haemorrhage or exudates
- No re-appearance or further worsening of OCT indicators of CNV disease activity on subsequent follow up following recent discontinuation of treatment
- No additional lesion growth or other new signs of disease activity on subsequent follow up following recent discontinuation of treatment
- No deterioration in vision that can be attributed to CNV activity.

If at any time there is presence of active disease, treatment will be resumed at an appropriate interval for the patient's disease state and previous response.

2.5 Switching treatments

A maximum of two switches between aflibercept and ranibizumab are permitted.

Re-loading of anti-VEGF treatment is not always indicated when switching a patient between agents. This will be considered on an individual patient basis.

Switching between the two treatments can be considered in the following circumstances:

- If a patient does not respond to first line treatment e.g. no improvement on OCT after the initial 3 loading dose injections (primary non responders) or a high number of injections is required (≥ 6 in the first 6 months) (secondary non responders)
- Severe inflammatory response – no longer appropriate for that agent to be used

2.6 In-tariff treatments

Photodynamic therapy (PDT)

- 5-10% of all clinically diagnosed AMD patients are considered to be non-responders to anti VEGF agents or they may have a rare variant of AMD – polypoidal vasculopathy
- These patients may be treated with a combination of PDT and anti VEGF agents.
- At least 3 PDT sessions at 12 week intervals may be required before treatment is considered to be a failure.

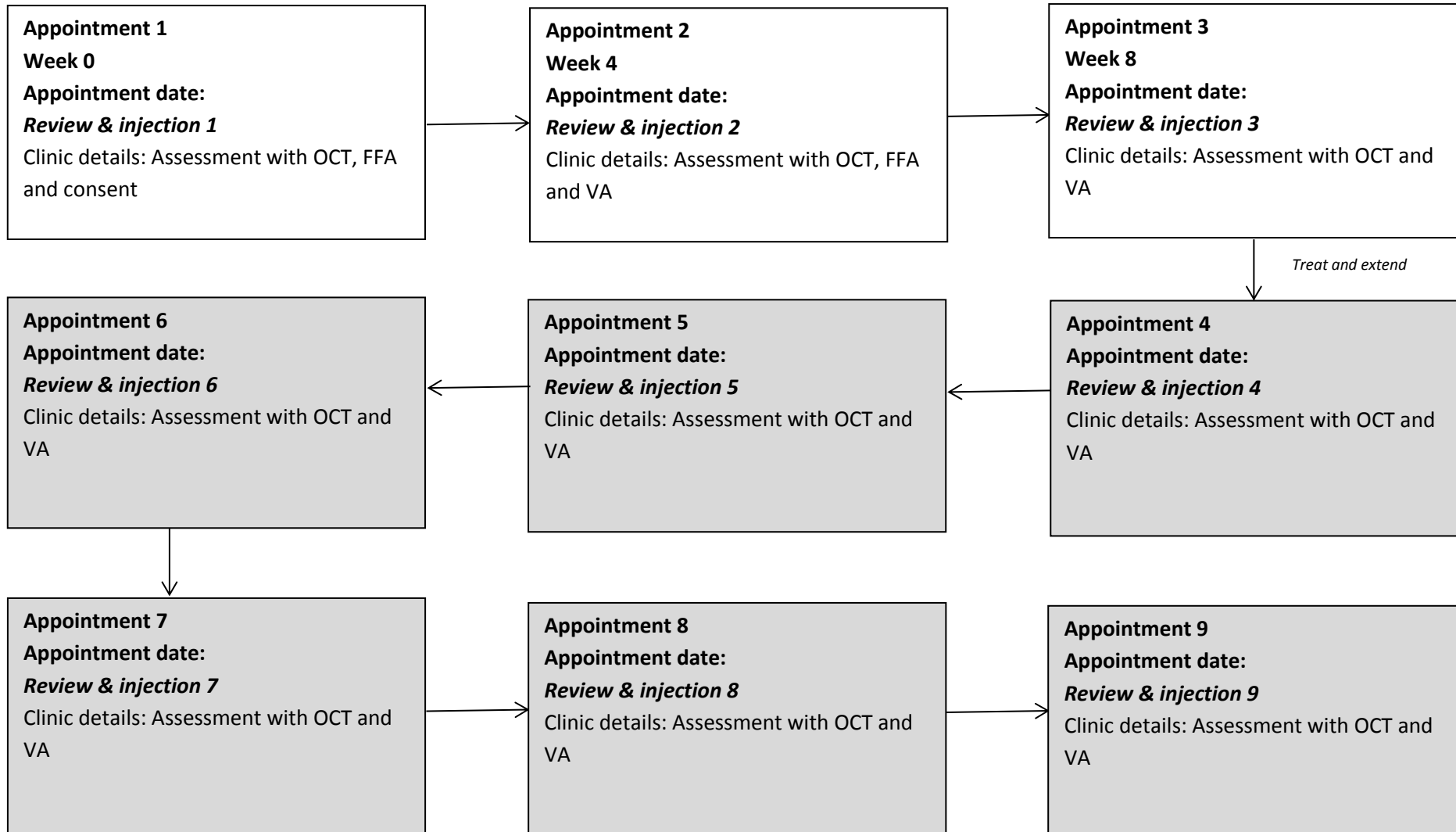
Reference

1. NICE technology appraisal guidance 155. Ranibizumab and pegaptanib for the treatment of age related macular degeneration. NICE last updated May 2012. NICE. Accessed online via <https://www.nice.org.uk/guidance/ta155/resources/guidance-ranibizumab-and-pegaptanib-for-the-treatment-of-agerelated-macular-degeneration-pdf>

Wet AMD clinic appointment schedule

Year 1


Treatment with ranibizumab or aflibercept




Intervals between appointments 4, 5, 6, 7, 8 and 9, if applicable will vary based on patient response (can be increased or decreased by 2weeks according to response)

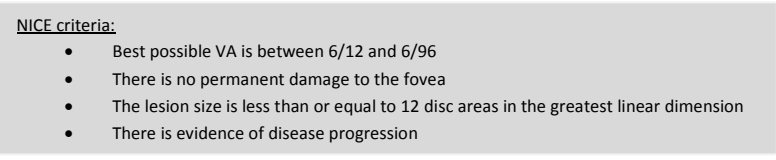
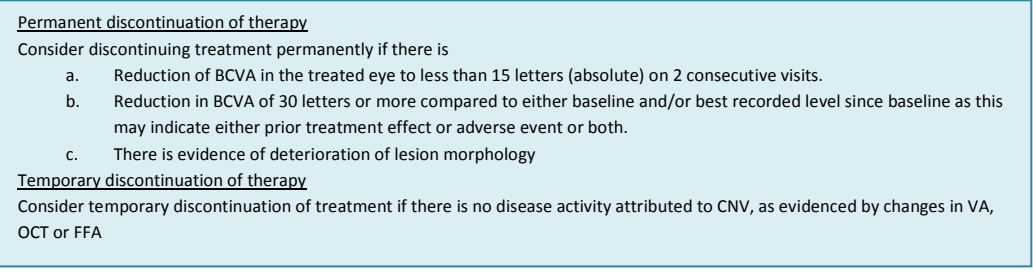
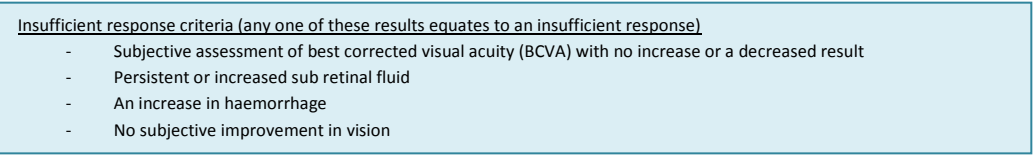
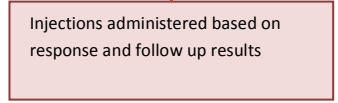
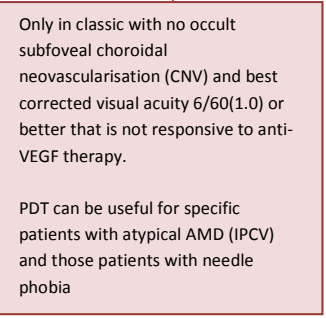
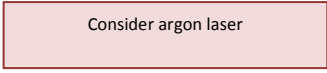
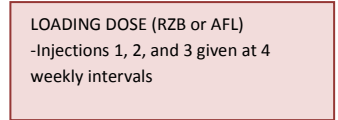
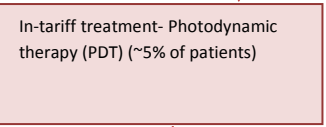
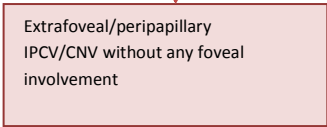
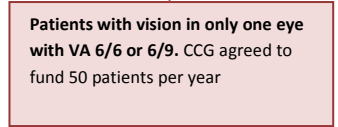
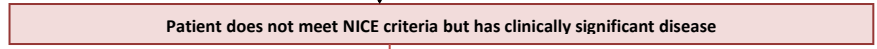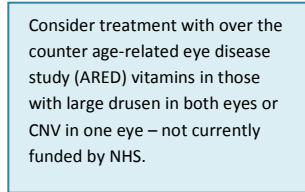
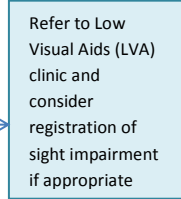
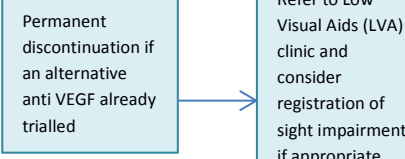
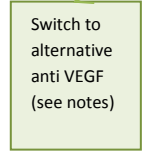
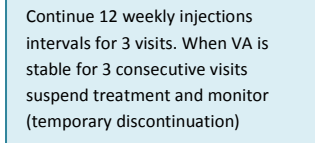
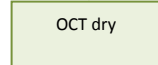
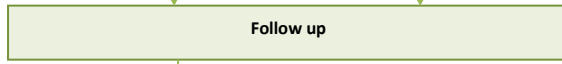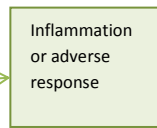
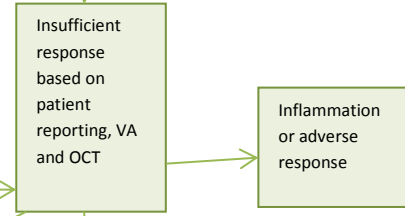
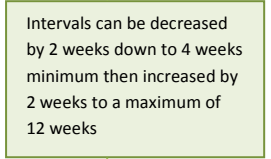
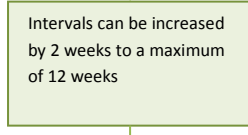
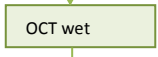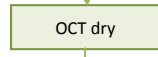
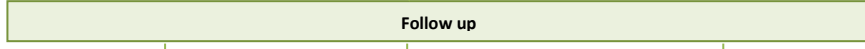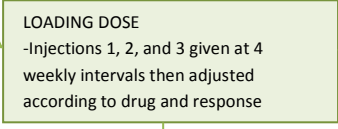
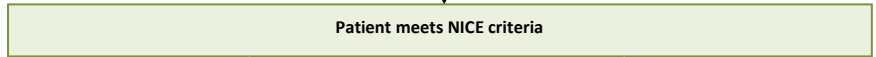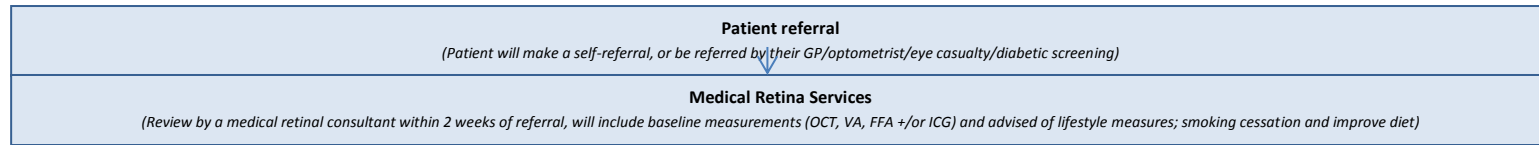
Tariff codes: BZ23Z – vitreous retinal procedure, WF01A – follow up ophthalmology

Key

 Loading phase

 Treat and extend phase

Pathway for treatment of neovascular AMD with anti VEGF agents



3. Diabetic macular oedema (DMO)

Diabetic Macular Oedema (DMO) is a condition which is a major complication of, and the most common cause of vision loss in, diabetes. Microvascular damage which is caused secondary to diabetes leads to the development of maculopathy and causes development of micro-aneurysms which leak fluid into the macular region. This can lead to loss of vision. DMO is a more chronic condition and affects younger patients compared to wet AMD. The condition affects the central vision. Central vision can also be affected by the growth of abnormal vessels that cause bleeding within the eye which can lead to complete blindness¹.

The incidence of the condition is expected to increase as diabetes becomes more common across the UK. Approximately 7-10% (varies according to ethnic group) of patients with diabetes have DMO and 10% of this population are estimated to have clinically significant macular oedema. If untreated, DMO has a 25-30% risk of developing into clinically significant macular oedema and up to 33% of eyes with DMO experience moderate vision loss. Vision loss from DMO is considered to be one of the most common causes of visual impairment in the working population of the Western World².

The National Institute for Health and Care Excellence (NICE) recommends that there are four agents currently available for the treatment of DMO; ranibizumab⁴, aflibercept⁶, dexamethasone⁷ and fluocinolone acetonide⁵.

The anti VEGF agents ranibizumab and aflibercept are indicated as first line treatments for the management of DMO when central retinal thickness is equal or greater to 400µm at the start of treatment⁴. Dexamethasone or Fluocinolone acetonide are indicated as second line treatments for patients who do not have glaucoma (as steroid treatment may further increase intraocular pressure) and for those that have had cataract surgery with an artificial lens in the eye to be treated (pseudophakia). The DMO must also have not responded to other treatments such as anti-VEGF agents or laser treatment.⁵ (see table below).

3.1 NICE criteria

Treatment for DMO can only be started if the following criterion is met;

- The eye must have a central retinal thickness of 400µm or more at the start of anti-VEGF treatment.

Criteria for different treatments;

Drug treatment	Criteria for use	Place in therapy
Anti VEGF agent	CRT > or equal to 400µm	First line
Dexamethasone intravitreal implant	<ul style="list-style-type: none">• Patient has an intraocular (pseudophakic) lens• Treatment with antiVEGF agent or laser has been unsuccessful or is unsuitable• Risk of glaucoma with a steroid must be discussed with patient	Second line (only for patients with a pseudophakic lens)
Fluocinolone acetonide implant	As above but to be used after the other three agents due to increased risk of glaucoma	Third line

Treatment with an anti VEGF consists of administering 5 loading dose injections at monthly intervals. Ranibizumab treatment is continued until the patient is stable whereas aflibercept can increase to an interval of 8 weeks after the initial five injections. Treatment should only

continue after the loading phase if there is evidence of response (demonstrated by an improved VA or OCT). If there is no response anti VEGF treatment should be stopped. If the patient has a pseudophakic lens then they can be considered for treatment with intravitreal dexamethasone, fluocinolone or laser.

Dexamethasone or fluocinolone should be considered second and third line respectively for patients who meet the NICE criteria.

Patients who have non centre involving macular oedema (no thickening in central 1mm zone) should be considered for treatment with macular laser if they have clinically significant macular oedema (CSMO).

Patients whose macular oedema is not clinically significant are observed every 3-4 months and risk factors e.g. weight, cholesterol, BP and glycaemic control, addressed.

3.2 Choice of treatment agent

All patients will receive 5 anti VEGF injections during the loading phase (unless there is a contraindication) and then be assessed for response. If there is no response at this stage or the patient develops an inflammatory response the patient should be considered for an alternative anti-VEGF treatment or for a steroid (if pseudophakic).

Six months of treatment is normally administered before a switch to an alternative agent is considered. An alternative anti VEGF is then administered for a maximum of 6 months before response is assessed and a steroid initiated if the response is still poor and the patient is pseudophakic. If the patient is pseudophakic- a steroid could be considered after the initial 6 months of treatment if limited response is seen with anti-VEGF treatment.

If a patient receiving treatment with an anti-VEGF becomes pregnant at any stage of the treatment cycle they should be discontinued on anti VEGF therapy and considered for treatment with dexamethasone or fluocinolone acetonide (if pseudophakic) or laser.

If a patient receiving treatment with an anti-VEGF has a myocardial infarction (MI) or a cerebrovascular accident (CVA) they will need to discuss treatment options with the clinician and a decision reached based on the benefit and risks of different treatments.

If after 3 months of initial treatment with an anti-VEGF agent, the patient's vision has improved to 6/6 and the OCT has normalised, the clinician may want to temporarily withhold further treatment and monitor regularly and only restart therapy if the oedema returns or vision drops.

It is appropriate for DMO patients undergoing cataract surgery to receive treatment with dexamethasone (in line with the defined pathway) during surgery. Injecting the patient whilst they are anaesthetised removes the need for an intravitreal injection whilst conscious.

References

1. Macular Society – Support through central vision loss. Diabetic macular oedema viewed online 7/4/15 accessed online via <http://www.macularsociety.org/about-macular-conditions/other-macular-conditions/diabetic-macular-oedema>
2. Horizon Scanning Centre. Aflibercept (Eylea) for visual impairment due to diabetic macular oedema – 1st line. May 2013, viewed online 7/4/15, accessed online via www.hsc.nihr.ac.uk

3. The Diabetic Retinopathy Clinical Research Network. Aflibercept, Ranibizumab or Avastin for diabetic macular edema. *New England Journal of Medicine* 2015; 372: 1193-1203
4. Ranibizumab for treating diabetic macular oedema (rapid review of technology appraisal guidance 237). NICE technology appraisal guidance (TA274). NICE. Viewed online 7/4/15, accessed online via <https://www.nice.org.uk/guidance/ta274/chapter/2-The-technology>
5. Fluocinolone acetonide intravitreal implant for treating chronic diabetic macular oedema after an adequate response to prior therapy (rapid review of technology appraisal guidance 271). NICE technology appraisal guidance (TA301). NICE viewed online 7/4/15, accessed online via <https://www.nice.org.uk/guidance/ta301>
6. Aflibercept for treating diabetic macular oedema. NICE technology appraisal guidance (TA346). NICE. Viewed online 7/12/15, accessed online via <http://www.nice.org.uk/guidance/ta346>
7. Dexamethasone for treating diabetic macular oedema. NICE technology appraisal guidance (TA349). NICE. Viewed online 7/12/15, accessed online via <http://www.nice.org.uk/guidance/ta349>
8. Early treatment Diabetic Retinopathy study. *Ophthalmology* 1991 May;98(5 Suppl):766-85.

Date of approval: April 2018

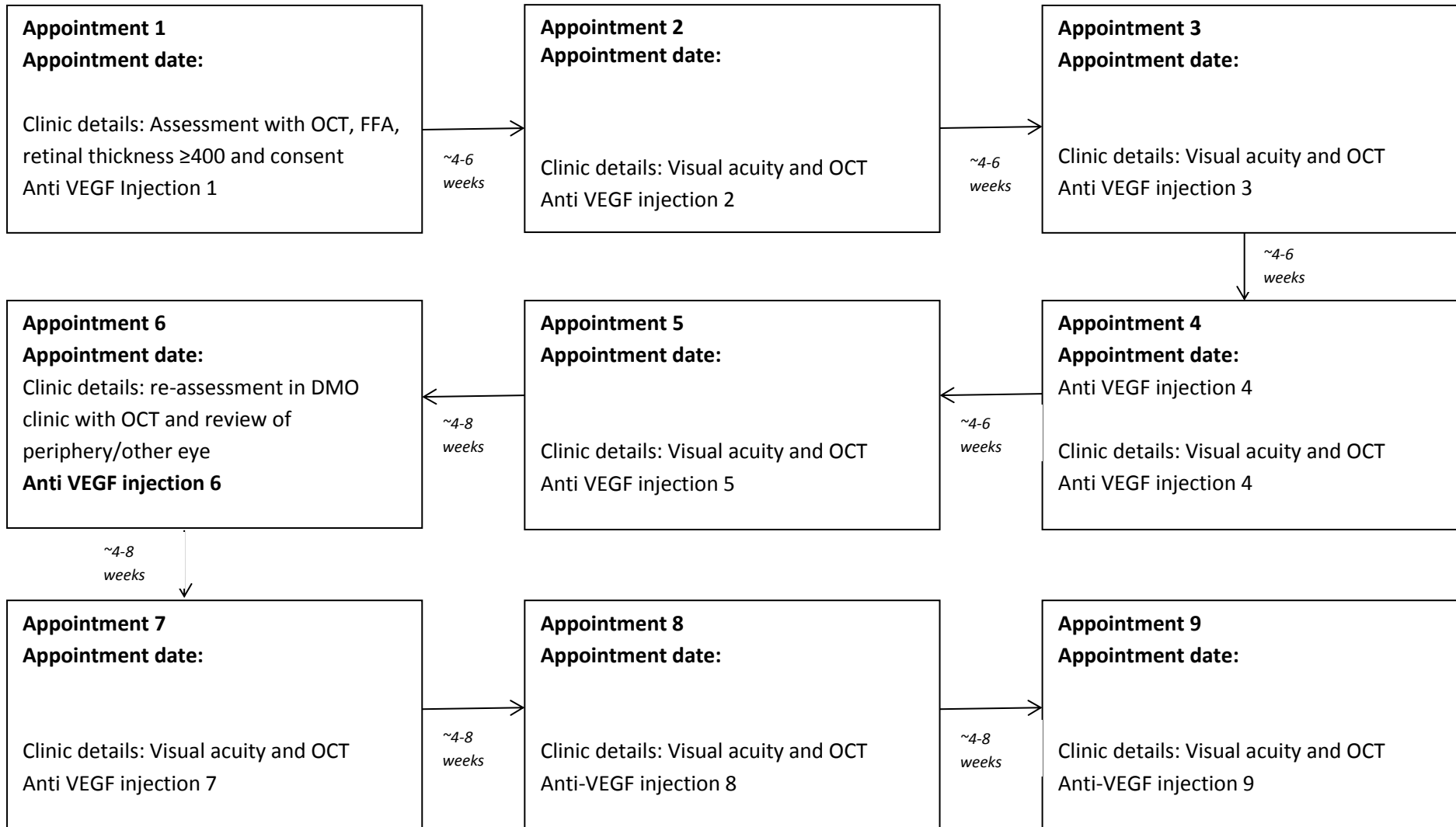
Review date: April 2019

South East London Area Prescribing Committee. A partnership between NHS organisations in South East London: Bexley/ Bromley/ Greenwich/ Lambeth/ Lewisham
Southwark Clinical Commissioning Groups (CCGs) & GSTFT/KCH/SLAM/Oxleas NHS Foundation Trusts & Lewisham & Greenwich NHS Trust

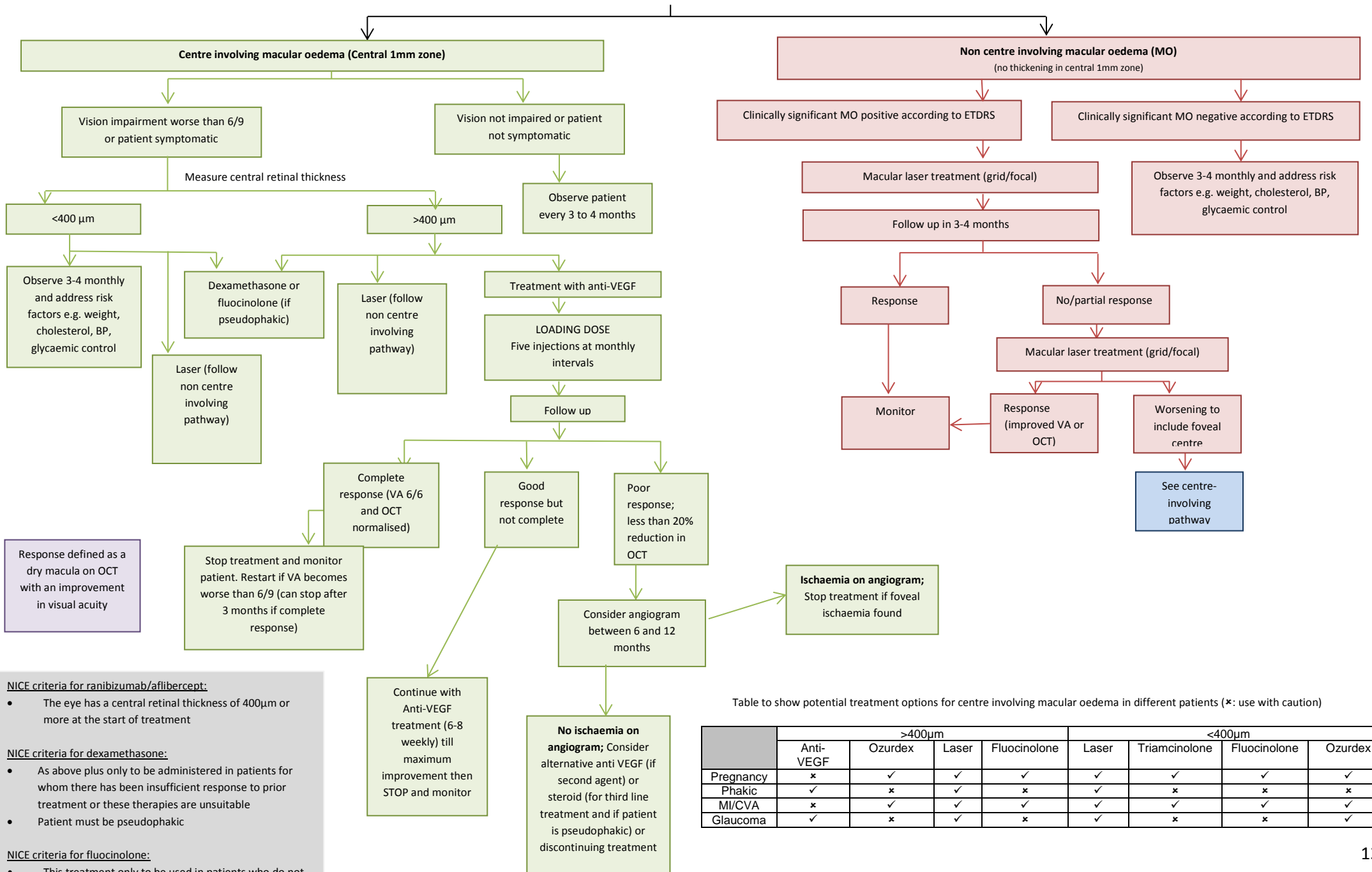
Not for commercial or marketing purposes. Strictly for use within the NHS

DMO clinic appointment schedule

Year 1



Pathway for treatment of Diabetic Macular Oedema



- NICE criteria for ranibizumab/afibercept:**
- The eye has a central retinal thickness of 400μm or more at the start of treatment
- NICE criteria for dexamethasone:**
- As above plus only to be administered in patients for whom there has been insufficient response to prior treatment or these therapies are unsuitable
 - Patient must be pseudophakic
- NICE criteria for fluocinolone:**
- This treatment only to be used in patients who do not respond to all other available agents
 - Patient must be pseudophakic

Table to show potential treatment options for centre involving macular oedema in different patients (*: use with caution)

	>400μm				<400μm			
	Anti-VEGF	Ozurdex	Laser	Fluocinolone	Laser	Triamcinolone	Fluocinolone	Ozurdex
Pregnancy	*	✓	✓	✓	✓	✓	✓	✓
Phakic	✓	x	✓	x	✓	x	x	x
MI/CVA	x	✓	✓	✓	✓	✓	✓	✓
Glaucoma	✓	x	✓	x	✓	x	x	✓

4. Central retinal vein occlusion

Retinal vein occlusions (RVOs) are the second most common type of retinal vascular disorder after diabetic retinal disease. An RVO can occur at any age (most common in people over 50 years old) and the severity can range from asymptomatic to a painful eye with severe visual impairment. RVO is the most common cause of sudden painless unilateral loss of vision. The occlusion can occur in either the central or branch retinal veins¹.

Central retinal vein occlusion (CRVO) is a condition where the central vein of the eye is blocked. The blockage reduces blood flow and leads to multiple haemorrhages within the retina. The blockage also causes damage to blood vessels which leads to leakage of fluid into the macular area (macular oedema). This often results in painless loss of vision. Retinal vein occlusion can also cause a decrease in blood supply, resulting in ischaemia². The vein occlusion is classed as an ischaemic vein occlusion when greater than 10 disc areas of capillary drop-out is seen on fluorescein angiography.

The cause of CRVO is not known but it occurs due to a blockage in the central retinal vein. There are several factors which increase the risk of developing the condition; atherosclerosis, glaucoma, inflammation and swelling of the optic nerve, changes in the blood vessel wall or blood clotting disorders².

There are two types of CRVO: ischaemic and non-ischaemic¹.

Ischaemic CRVO: A severe form of CRVO severe visual impairment with a marked afferent pupillary defect. There is severe disc oedema and haemorrhages are scattered throughout the fundus, greater than 10 disc areas on fluorescein angiography. Ischaemic CRVO carries a high risk of neovascular glaucoma (a serious form of glaucoma which can result in blindness) which can be prevented by regular treatment with an anti-VEGF.

Non-ischaemic CRVO: Mild or absent afferent pupillary defect. There is some disc oedema and there are widespread retinal haemorrhages and flame haemorrhages¹. Less than 10 disc areas of capillary drop out is seen on fluorescein angiography. Non-ischaemic CRVO carries a lower risk of neovascular glaucoma, although 34% can convert to an ischaemic CRVO over 3 years (CVOS Study- Arch 1997)⁶.

4.1 NICE guidance

NICE recommends treatment of macular oedema secondary to CRVO with an intravitreal injection of an anti-VEGF agent, ranibizumab or aflibercept, or an intravitreal implant of the steroid dexamethasone. Patients with CRVO should be treated monthly until a maximum VA is achieved and visual and anatomical outcomes are stable for 3 consecutive monthly assessments. Once the eye is stable the patient can be treated on an as required basis based on objective assessment of VA and OCT.

If there is no improvement in vision after 3 injections the clinical team should consider stopping treatment. If no improvement after 6 months then an FFA should be undertaken. If the FFA shows significant foveal ischaemia, the patient should not receive further treatment but will need to be monitored for 3-6 months. If there is no significant ischaemia or glaucoma the patient can be switched to dexamethasone intravitreal implant.

4.2 Management of patients who do not respond to their first treatment

There is limited evidence regarding how to treat patients who do not respond to the first line agent and the NICE guidance does not explicitly state whether or not it is appropriate to try a different agent.

Patients who do not respond to an injection of dexamethasone should be considered for an alternative treatment, primarily an anti-VEGF treatment.

Patients who are initially treated with an anti-VEGF agent but subsequently become pregnant or suffer an MI or CVA should switch treatment to dexamethasone. Similarly, patients who are treated with dexamethasone but subsequently develop glaucoma should be considered for treatment with an anti-VEGF agent.

If a patient is switched from one agent to another careful monitoring of response is essential to ensure that there is an improvement in the visual acuity. Treatment with any second line agent should be discontinued if there is no improvement after 3-6 months.

4.3 Use of bevacizumab

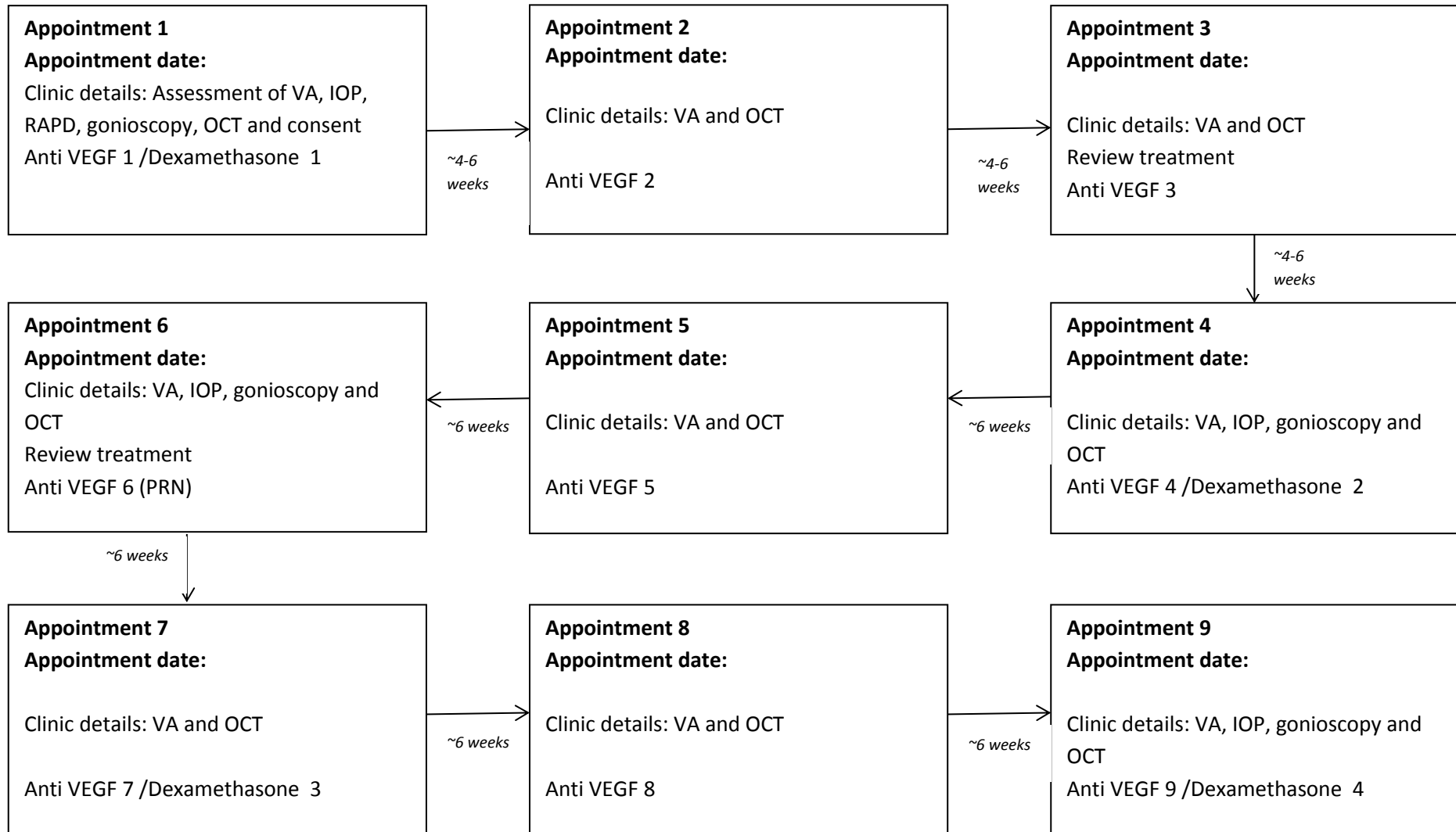
Treatment with bevacizumab is outside of current NICE guidance and therefore not routinely commissioned.

References

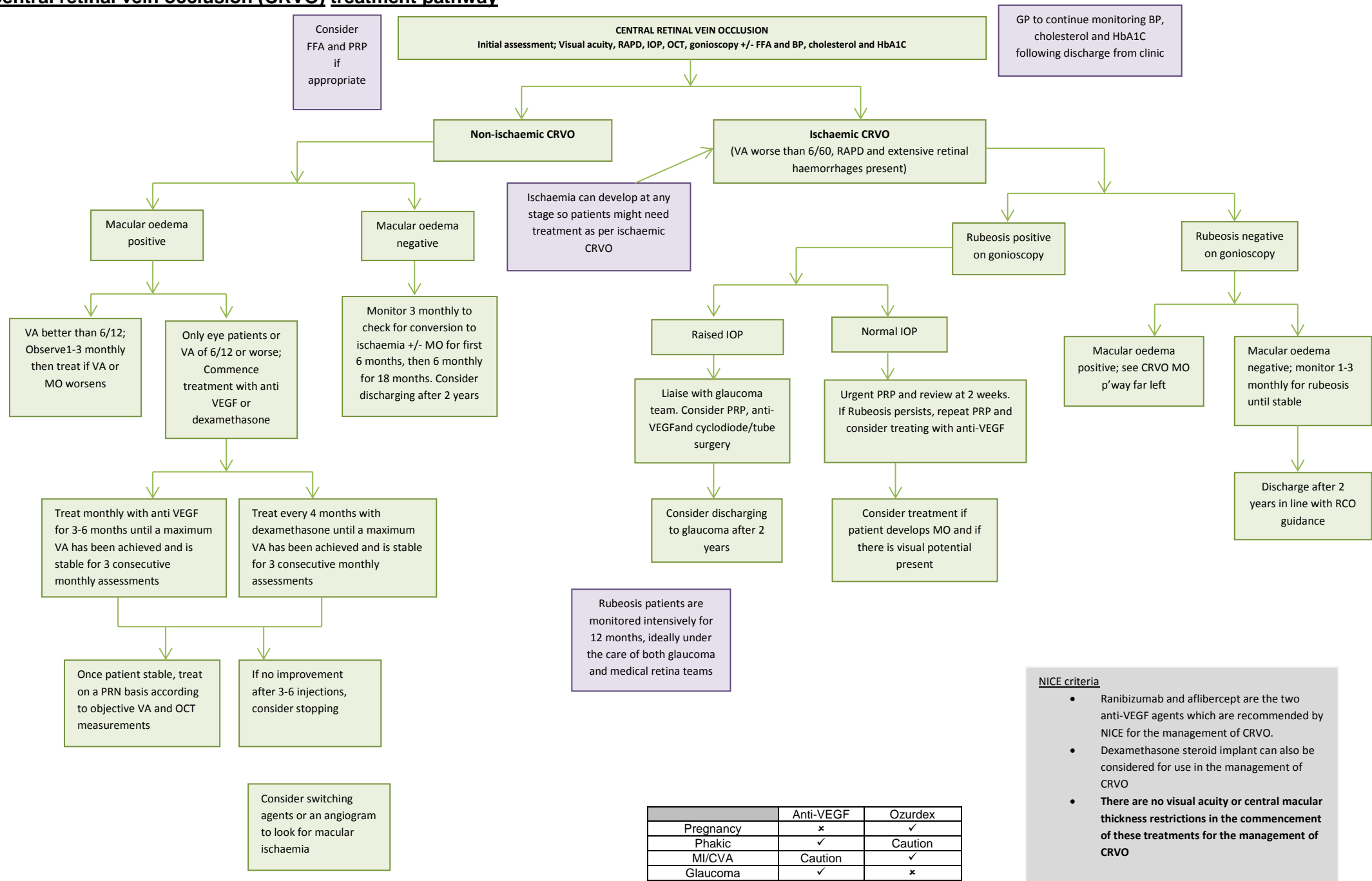
1. H. Willacy, C. Tidy. Retinal Vein Occlusions. Last updated April 2014. Viewed online 22/5/15 accessed via <http://www.patient.co.uk/doctor/retinal-vein-occlusions>
2. Bayer Healthcare pharmaceuticals. Central Retinal Vein occlusion (CRVO) viewed online 22/5/15 accessed via <https://pharma.bayer.com/en/therapeutic-areas/therapeutic-areas-a-z/central-retinal-vein-occlusion-crvo.php>
3. Aflibercept for treating visual impairment caused by macular oedema secondary to central retinal vein occlusion. Feb 2015. NICE technology appraisal guidance 305. Viewed online 22/5/15 accessed via <http://www.nice.org.uk/guidance/ta305/chapter/4-Consideration-of-the-evidence>
4. Ranibizumab for treating visual impairment caused by macular oedema secondary to retinal vein occlusion. Viewed online 22/5/15. Accessed online via <http://www.nice.org.uk/guidance/ta283/chapter/2-The-technology>
5. Dexamethasone intravitreal implant for the treatment of macular oedema caused by retinal vein occlusion. NICE appendix B. viewed online 22/5/15 accessed online via <http://www.nice.org.uk/guidance/ta229/documents/macular-oedema-retinal-vein-occlusion-dexamethasone-final-scope2>
6. CVOS-Natural history and clinical management of central retinal vein occlusion. The Central Vein Occlusion Study Group. Arch Ophthalmol October 1997

CRVO clinic appointment schedule

Year 1



Central retinal vein occlusion (CRVO) treatment pathway



NICE criteria

- Ranibizumab and aflibercept are the two anti-VEGF agents which are recommended by NICE for the management of CRVO.
- Dexamethasone steroid implant can also be considered for use in the management of CRVO
- There are no visual acuity or central macular thickness restrictions in the commencement of these treatments for the management of CRVO**

See table for suitable agents in different classes of patients.

	Anti-VEGF	Ozurdex
Pregnancy	✗	✓
Phakic	✓	Caution
MI/CVA	Caution	✓
Glaucoma	✓	✗

5. Branch retinal vein occlusion (BRVO)/ Hemi-vein occlusion (HVO)

The retina contains many blood vessels which are used to supply the eye with oxygen and nutrition. The retinal arteries and veins cross over each other at numerous locations in the retina. Occasionally, one of these arteries may compress one of the more fragile veins leading to a partial obstruction. They are most commonly seen in patients with atherosclerosis. Other factors that increase the risk of branch retinal vein occlusion (BRVO) include hypercholesterolaemia, hypertension and being overweight. The most common cause of vision loss in patients with BRVO is macular oedema. The build-up of pressure due to the obstruction can cause damage to the walls of the retina and bleeding into the retina. Damage to blood vessels can cause swelling in the macular region leading to blurring and loss of vision¹.

NICE recommends the use of anti-VEGF agents - ranibizumab or steroids - dexamethasone intravitreal implant for the management of BRVO^{2,3}.

Ranibizumab is recommended as a treatment option for treating visual impairment caused by macular oedema following BRVO only if treatment with laser photocoagulation has not been beneficial or when the laser photocoagulation is not suitable because of the extent of macular haemorrhage and only if the manufacturer provides ranibizumab with the discount agreed in the patient access scheme. An intravitreal injection is administered monthly for 3 months until maximal visual acuity is achieved (usually 3 or more injections). Monitoring and treatment intervals will be determined by the treating clinician. If there is no response after three months treatment will be reviewed and an alternative agent considered.

NICE recommends dexamethasone can be used as a treatment option for the treatment of macular oedema following BRVO when treatment with laser photocoagulation has not been beneficial or when the laser photocoagulation is not suitable because of the extent of macular haemorrhage. It is not indicated for use in young patients or patients with glaucoma. Patients who are started on dexamethasone may need to have interim visits to measure pressures. The implants can be repeated, usually at four to six monthly intervals up to a maximum of six implants³.

Aflibercept, an alternative anti-VEGF agent is currently being reviewed by NICE with regards to its use in BRVO.

5.1 Switching treatments

If there is no response after the initial loading dose of anti-VEGF treatment (3 injections at monthly intervals) the patient should be considered for an alternative treatment option such as treatment with dexamethasone or laser if the oedema is not too close to the fovea.

If there is no response after the initial treatment with steroids treatment should be reviewed and an alternative such as laser or anti-VEGF should be considered.

If there is no response after the initial treatment with laser, treatment should be reviewed and an alternative such as anti-VEGF or dexamethasone should be considered.

Table to show the different potential treatment option for BRVO in different patient groups

	Anti-VEGF	Ozurdex	Laser
Pregnancy	x	✓	✓
Phakic	✓	✓	✓
MI/CVA	Caution	✓	✓
Glaucoma	✓	x	✓

5.2 Management of patients who do not respond after 3 injections

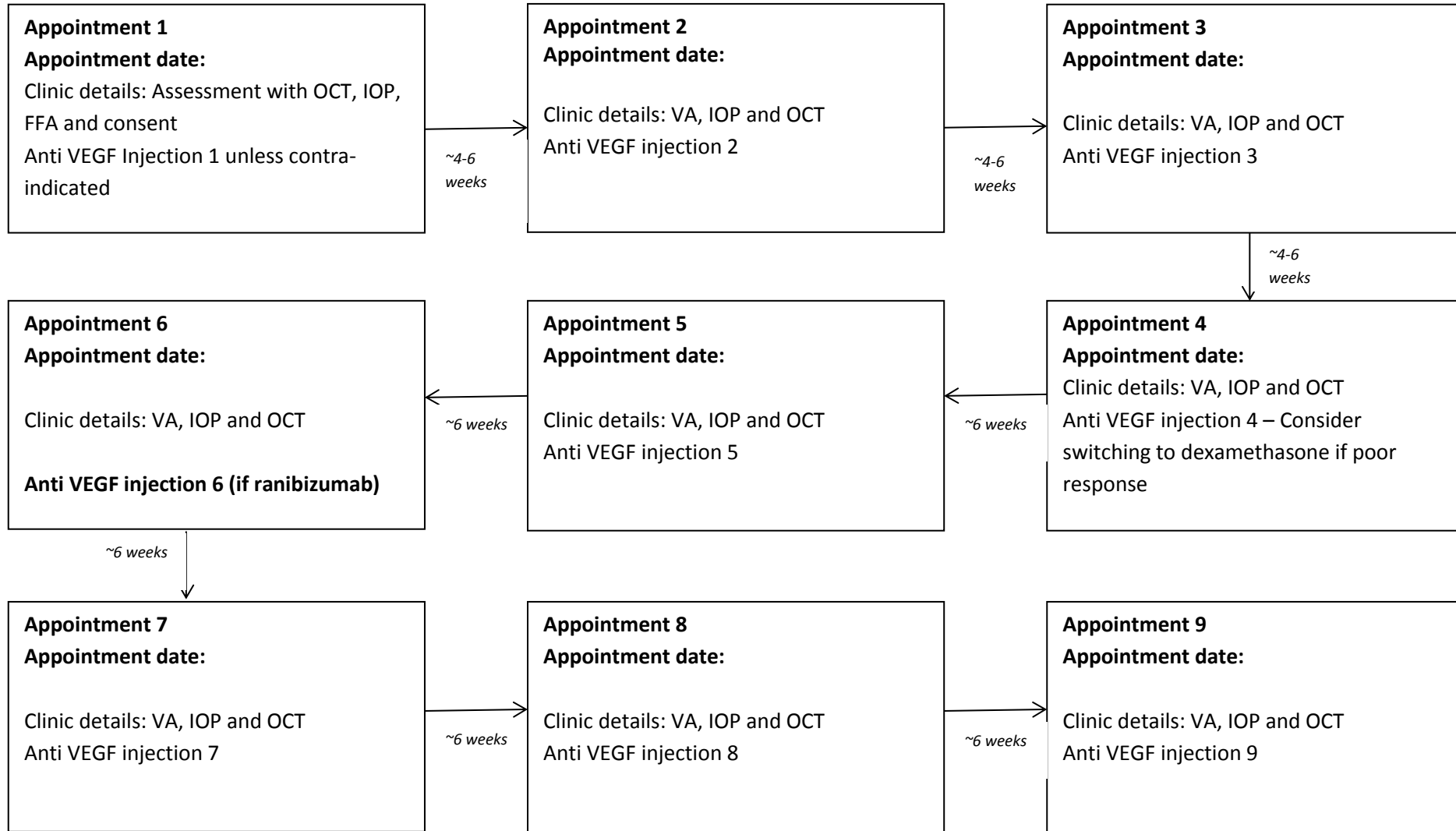
A loading dose of 3 injections at monthly intervals is recommended. If there is no response at this stage NICE has recommended that the treatment should be switched. It is recommended that treatment continues until visual and anatomical outcomes are stable for 3 consecutive assessments.

References

1. Branch Retinal Vein Occlusion. Viewed online 15/5/15 accessed via <http://www.retinacarecenter.com/conditions/branch-retinal-vein-occlusion-brvo>
2. Ranibizumab for treating visual impairment caused by macular oedema secondary to retinal vein occlusion. NICE technology appraisal guidance [TA283]. May 2013. Viewed online 15/5/15 accessed via <http://www.nice.org.uk/guidance/ta283/chapter/1-Guidance>
3. Dexamethasone intravitreal implant for the treatment of macular oedema secondary to retinal vein occlusion. NICE technology appraisal guidance 229. July 2011. Viewed online 15/5/15 accessed via <http://www.nice.org.uk/guidance/ta229/resources/guidance-dexamethasone-intravitreal-implant-for-the-treatment-of-macular-oedema-secondary-to-retinal-vein-occlusion-pdf>
4. British National Formulary 68. BMJ Publishing Group Ltd. September 2014. P 762
5. British National Formulary 68. BMJ Publishing Group Ltd. September 2014. P 746

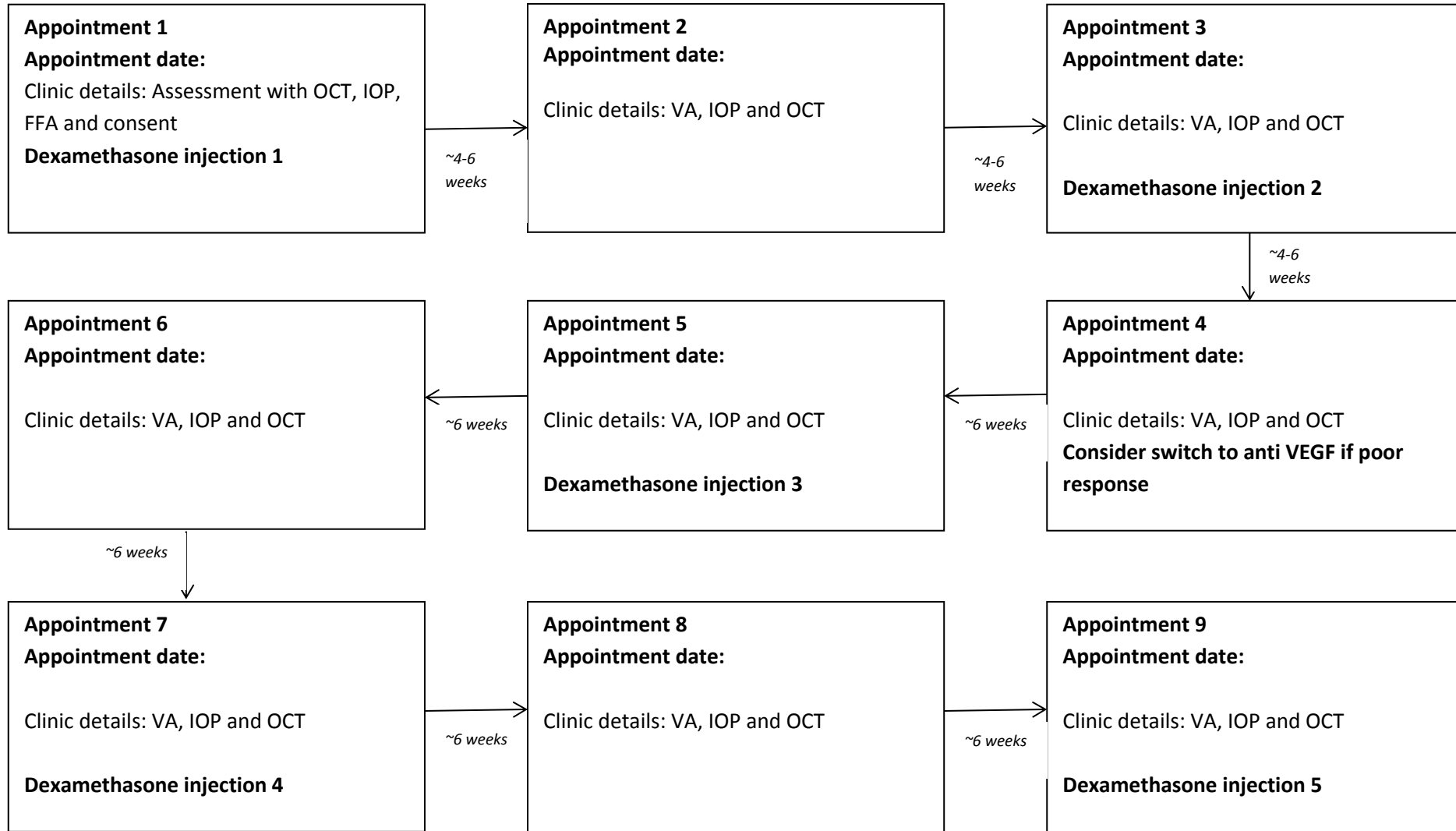
BRVO clinic appointment schedule; treatment with anti VEGF agent

Year 1

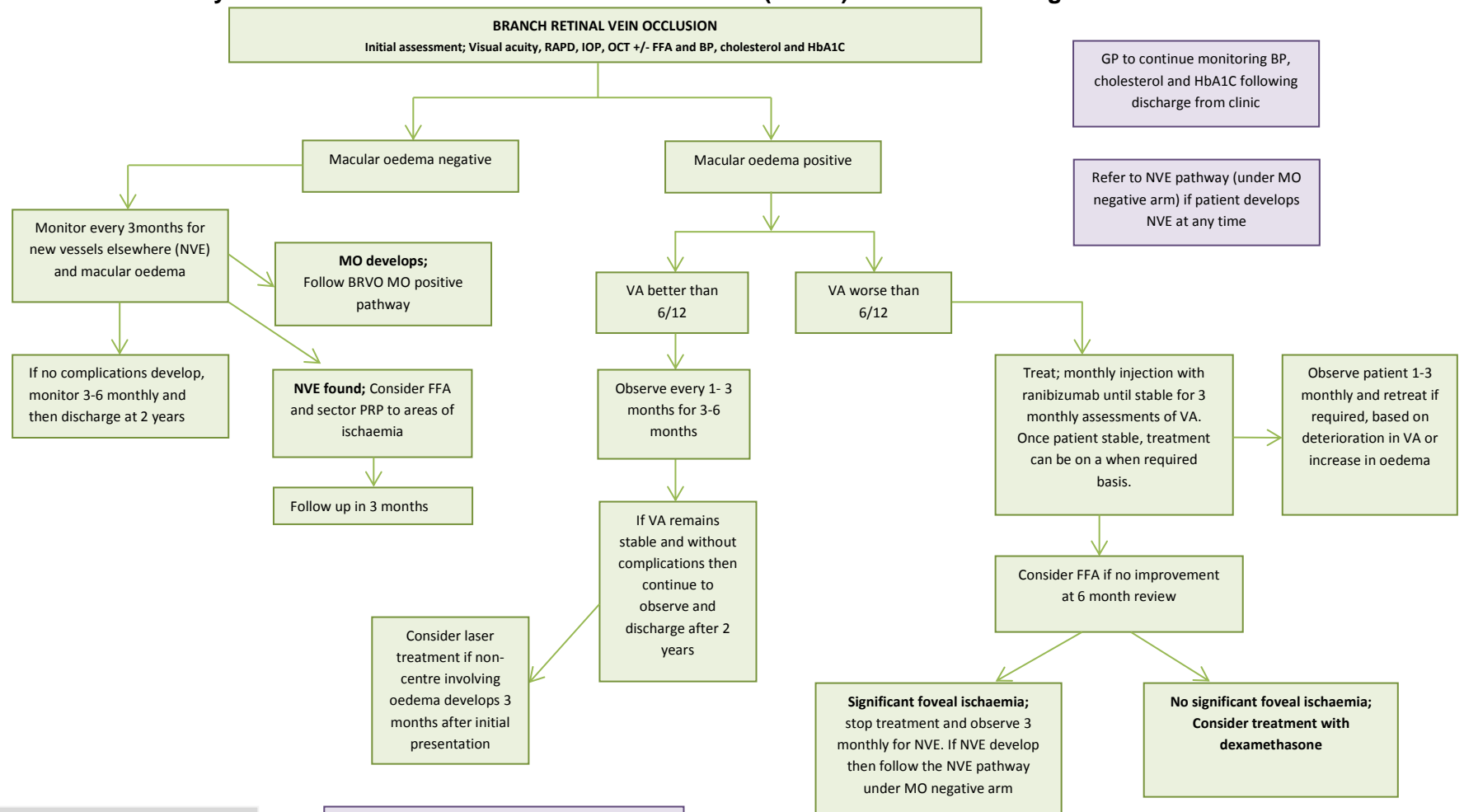


BRVO clinic appointment schedule; treatment with dexamethasone

Year 1



Pathway for treatment of Branch retinal vein occlusion (BRVO) with anti VEGF agents



NICE criteria for ranibizumab:

- Recommended as a treatment option for treating visual impairment caused by macular oedema following BRVO only if treatment with laser photocoagulation has not been beneficial, or when the laser photocoagulation is not suitable because of the extent of macular haemorrhage.

AND

- Only if the manufacturer provides ranibizumab with the discount agreed in the patient access scheme.

NICE criteria for dexamethasone:

- Recommended when treatment with laser photocoagulation has not been beneficial, or when the laser photocoagulation is not suitable because of the extent of the macular haemorrhage.

Switching; - If switching to another agent within the same class then allow 3 months to assess for response.

If switching to a different class of agent then allow 6 months to assess for response.

Glossary

AMD	Age Related Macular Degeneration
Anti-VEGF	Anti- Vascular Endothelial Growth Factor agent (Drug which antagonises endogenous VEGF)
BRVO	Branch Retinal Vein Occlusion
CNV	Choroidal NeoVascularisation
CRVO	Central Retinal Vein Occlusion
CVA	Cerebral Vascular Accident
DMO	Diabetic Macular Oedema
FAZ	Foveal Avascular Zone
FFA	Fundus Fluorescein Angiography
IOP	Intra Ocular Pressure
IPCV	Idiopathic Polypoidal Choroidal Vasculopathy
LVA	Low Vision Assessment
MI	Myocardial Infarction
MO	Macular Oedema
NVE	NeoVascularisation Elsewhere
OCT	Optical Coherence Tomography
PDT	Photo-Dynamic Therapy
PRP	Pan Retinal Photocoagulation
RAPD	Relative afferent papillary defect
VA	Visual Acuity

Date of approval: April 2018

Review date: April 2019

South East London Area Prescribing Committee. A partnership between NHS organisations in South East London: Bexley/ Bromley/ Greenwich/ Lambeth/ Lewisham
Southwark Clinical Commissioning Groups (CCGs) & GSTFT/KCH/SLAM/Oxleas NHS Foundation Trusts & Lewisham & Greenwich NHS Trust

Not for commercial or marketing purposes. Strictly for use within the NHS